

Ozone therapy enhances the effectiveness of chemotherapy and reduces its adverse reactions, improving the quality of health in ovarian epithelial cancer

Peeter Francisco Jaramillo Cazco ^a, Daniel Adolfo Morales Fiallo ^b,
Gregorina del Carmen González Perdomo ^c, Gabriel Enrique Maldonado Salcedo ^d.

- a. Licenciado en Salud. Centro de Terapia Dr. Ozono. ORCID: <https://orcid.org/0009-0009-4619-6006>
- b. Especialista en Cirugía Abdominal. Centro de Terapia Dr. Ozono. ORCID: <https://orcid.org/0009-0006-6987-1332>
- c. Magíster en Dirección. Centro de Terapia Dr. Ozono. ORCID: <https://orcid.org/0009-0009-1329-2317>
- d. Gabriel Enrique Maldonado Salcedo. Especialista en Anestesiología. Centro de Terapia Dr. Ozono. ORCID: <https://orcid.org/0009-0006-2062-0217>

[DOI: 10.22517/25395203.25624](https://doi.org/10.22517/25395203.25624)

Abstract

Objective: to apply O3T for tumor and nodular regression, enhancing the effectiveness of QMT and decreasing its adverse effects, for a better quality of health of the patient.

Materials and Methods: quasi-experimental, longitudinal research, where the methods of comparative analysis, cause-effect relationship and data triangulation were used. Data was collected by: VAS pain scale, SAS, KPS and direct observation.

Results: diagnosis before O3T was signs of high metabolic grade tumor pathology in solid peritoneal implant attached to the sigmoid colon, adenopathy versus peritoneal implants in the sigmoid mesocolon, adenopathy of the left common iliac chain, left retroperitoneal para-aortic adenopathy and subsolid pulmonary nodule in the lateral segment of the right lower lobe. After O3T it was evidenced: absence of tumor pathology of moderate/high metabolic grade, disappearance of pulmonary nodule of the right lower lobe and complete response of pelvic adenopathies and pelvic peritoneal implants to QMT.

Discussion: it was demonstrated that O3T potentiates the effectiveness of QMT and reduces its adverse reactions, improving the patient's quality of health.

Conclusions: it was demonstrated that there is correspondence between O3T treatment with the effectiveness of QMT, the tumor pathology and the adverse reactions of QMT, obtaining improvement in the quality of health of the patient.

Key words: ozone therapy; ovarian epithelial cancer, chemotherapy.

Resumen

Objetivo: aplicar O3T para la regresión tumoral y nodular, potenciando la efectividad de la QMT y disminuyendo de sus efectos adversos, para una mejor calidad de salud de la paciente.

Materiales y Métodos: investigación quasiexperimental, longitudinal, donde se utilizaron los métodos de análisis comparativo, relación causa-efecto y triangulación de datos. Los datos fueron recolectados por: escala del dolor EVA, SAS, KPS y observación directa.

Resultados: el diagnóstico antes de la O3T fue de signos de patología tumoral de alto grado metabólico en implante peritoneal solido adherido al colon sigmoideo, adenopatía versus implantes peritoneales en el mesocolon del sigmoideo, adenopatía de la cadena iliaca común izquierda, adenopatía retroperitoneal paraaórtica izquierda y nódulo pulmonar subsolido en el segmento lateral del lóbulo inferior derecho. Luego de la O3T se evidenció: ausencia de patología tumoral de moderada/alto grado metabólico, desaparición de nódulo pulmonar del lóbulo inferior derecho y respuesta completa de las adenopatías pélvicas y de los implantes peritoneales pélvicos a la QMT.

Discusión: se demostró que la O3T potencia la efectividad de la QMT y reduce sus reacciones adversas, mejorando la calidad de salud en la paciente.

Conclusiones: se demostró que existe correspondencia entre el tratamiento de O3T con la efectividad de la QMT, la patología tumoral y las reacciones adversas de la QMT, obteniéndose mejora en la calidad de la salud en la paciente.

Palabras claves: ozonoterapia; cáncer epitelial ovárico, quimioterapia

Introduction

Cancer cells, according to Sáez et al. (1), have the general characteristic of proliferating without measure, undergoing a mutation that alters their function by means of meiotic cell division in an abnormal manner, invading adjacent tissues beyond normal limits and extending to other organs.

In the case of Quito, "since 1985, incidence and mortality rates for ovarian cancer have increased continuously and significantly. On average, incidence has increased by 1.3% and mortality by 2.8% each year"(2). Damian et al. (3,4) reported that new cases, and 207 patients died, the first stage of the disease is asymptomatic or with little symptomatology, so the diagnosis is often late. "The acquisition of mesenchymal cell capacities by epithelial cells implies a malignant progression of these cells through a biological process in which epithelial cell markers are suppressed"(5).

The treatment of CEO depends on its stage: "20% of patients may present with tumor lesions that are limited to the ovaries (stage I), while 5% of cases include stage II cases" (3).

The American Cancer Society (6) points out that the drugs used to treat CEO are considered systemic therapies. In this regard, Reyes et al. (7), states that ozone therapy (O3T) increases the efficacy of chemotherapy (QMT) and helps to reduce its side effects by activating the cell's antioxidant systems.

According to Fernando (8,9,10), the medicinal ozone is analgesic and anti-inflammatory and inactivates metabolic mediators of pain; it also reduces phagocytic capacity and superoxide production.

In this regard, "ozone therapy improves body oxygenation, modulates inflammatory processes, increases the immune response and improves diseases" (11).

Likewise, according to Ferguson (12,13,14,15), when O3T is applied in parallel to QMT, the former enhances the antitumor action of the latter, proving to be an effective complementary treatment to conventional cancer treatments. O3T produces restitution of basal oxidative stress; in the case of osteosarcoma, it provides improvements in clinical variables of pain, inflammation and function, derived from the adverse effects of QMT and radiotherapy. "The application of ozone therapy as a complementary treatment is suitable and safe, offering positive effectiveness in the treatment of chronic pain and numerous diseases, constituting a very effective therapeutic palliative" (16).

Bañuelos (17) refers that O3T provides regression of tumor hypoxia, this being due to its oxygenation capacity, thus avoiding carcinogenic cellular aging.

Gavilan (18) states that O3T of oxidative preconditioning generates protection: anti-inflammation, immunomodulating and revitalizing the body, having as an effect the recovery of the patient. Ozone therapy “regulates oxidative stress caused by free radicals, ozone being exclusively the means of direct stimulation of enzymes that work as endogenous antioxidants, which decrease the level of oxidative stress” (19).

Regarding CEO scanning, PET-CT “is gaining ground as a scan to determine the extent of the disease, once the diagnosis of ovarian cancer has been made. It can sometimes provide more exhaustive information before deciding on treatment” (20), thus, in this study PET-CT was considered as imaging evidence due to its property of detecting peritoneal implants. Regarding the state of the art of this study, the comparison of results is shown in the following table.

Table 1. State of Art.
Research background

Autor(s)/year	Results
Ceballos et al. (2013)	Patient with prostate cancer, post-QMT. O3T treatment showed a remarkable clinical improvement.
Vélez (2015)	Patient with metastatic pancreatic cancer, received QMT simultaneously with O3T, resulting in increased quality of life and tumor regression.
Cobiellas et al. (2018)	Rectal insufflation of O3T in a patient with bone cancer, showing tumor regression and better symptomatic evolution.
Pérez et al. (2018)	IPO3 reduces cancer progression providing better quality of life.
Clavo et al. (2021)	Patient with chronic pelvic pain due to cancer, decreased significantly after three months of O3T.
Fergusson (2023)	Ozonated saline and minor autohemotherapy as complementary therapy, combined with radiotherapy. Fifteen months later the patient showed no side effects.
Alonso et al. (2023).	O3T as an adjuvant therapy in oncology is supported.
Jaramillo et al. (2024)	IPO3 improved symptomatic and morphological picture of patient with cervicitis.
Bañuelos (2023)	Synergy of O3T with some QMT drugs, raising proapoptotic gene levels and decreasing tumor hypoxia values.

Source: own elaboration

According to the state of the art and the patient's diagnosis, the general objective was formulated to apply O3T for tumor and nodular regression, enhancing the effectiveness of QMT and reducing its adverse effects, for a better quality of health of the patient. In relation to hypotheses and variables (Table 2), the following was designed:

Table 2. Hypotheses and variables.

Hypothesis: O3T activates tumor and nodular regression, enhancing the effectiveness of QMT and decreasing its adverse effects for a better quality of health of the patient		
Variables	Dimensions	Indicators
Independiente (VI): O3T		Function and symptoms
Dependent (VD 1): QMT	Functioning	Functional capacity
	Symptomatology	Exhaustion, nausea, loss of appetite and nervous hypersensitivity
Dependent (VD 2): CEO	Tumor pathology	Metabolic enhancement
		Pelvic adenopathy and pelvic peritoneal implants

This study contributes to:

Increase the effectiveness of QMT;

Decrease the adverse effects of QMT in patients with CEO; and

Improve the quality of health

Materials and methods

Databases such as Redalyc, ProQuest, LILACS, Scopus, PubMed, SJR, Cochrane and Scielo were used, applying search strategies with Boolean operators. Original articles and systematic literature reviews addressing the topic in the last five years were selected.

The population is represented by the universe of patients with CEO in Quito, Ecuador. The sample is a patient with CEO.

The design, materials, methods and procedures of this study include:

1. A quali-quantitative longitudinal case study, quali-quantitative methods were used to follow up the patient's evolution and compare it at two points in time (before and after O3T applied simultaneously with QMT)
2. The following data collection techniques were used: after each O3T session: direct observation (recording of blood pressure measurements, O2 saturation, electrocardiogram, and instruments, VAS scale questionnaire before and after O3T treatment (SAS and KPS

questionnaires), and imaging study by Pet-Scan before and after O3T treatment.

3. Methods of comparative analysis, cause-effect relationship and data triangulation were used.

The subject of this clinical case is a 40-year-old female patient (Table 3), with positron emission tomography PET CT study with FDG/14-12-2021, with diagnosis before O3T of endometrioid cystadenocarcinoma of the left ovary with regional and retroperitoneal nodal involvement. Solid peritoneal implant to the sigmoid colon with SUV max.7.82 measures 1.6 cms, adenopathy versus peritoneal implants in the sigmoid mesocolon with SUV max.of 9.47, measuring up to 1x 1.2 cms.

The procedure for the application of O3T (Table 3) was carried out with Medical Ozone equipment (MODEL MOP0.4-AD)

Table 3. O3T application protocol

Ciclo	SSO3 + AHTM + O3 rectal
1ero	8 sessions Rectal O3T +AHTMC +SSO 4 before and 4 after each QT+AHTMC +SSO
2do	8 sessions O3T rectal +AHTMC +SSO 33 before and 5 after each QT
3ro	7 sessions O3T rectal +AHTMC +SSO 4 before and 3 after each QT
4to	6 sessions O3T rectal +AHTMC +SSO 4 before and 2 after each QT
5to	8 sessions O3T rectal +AHTMC +SSO 4 before and 4 after each QT
6to	10 sessions O3T rectal +AHTMC +SSO 6 before and 4 after each QT
7mo	12 sessions O3T rectal +AHTMC +SSO 6 before and 6 after each QT
Legend	O3T= ozone therapy. AHTMC=major autohemotherapy. SSO=ozonized solution

Source: own elaboration

Results

Simultaneous application of O3T and QMT, evidenced:

1. Dependent variable 1. QMT. Performance: data are presented in Table 3.

Table 3. Patient's performance capabilities during O3T

Cycles	SCALE KPS	Daily tasks
1st	20	Seriously ill. Active supportive care
2nd	40	Incapacitated. Special care
3rd	50	Considerable help from others and frequent special care
4th	50	Considerable help from others and frequent special care
5th	60	Occasional help from others, but able to take care of self for most of her needs
6th	80	Moderate symptoms, normal activity
7th	90	Normal activity. Mild signs and symptoms of illness
One month later	100	Normal activity

Source: León²¹. Adaptation

2. Dependent variable 1. QMT. Symptomatology.

The results are presented in Table 4:

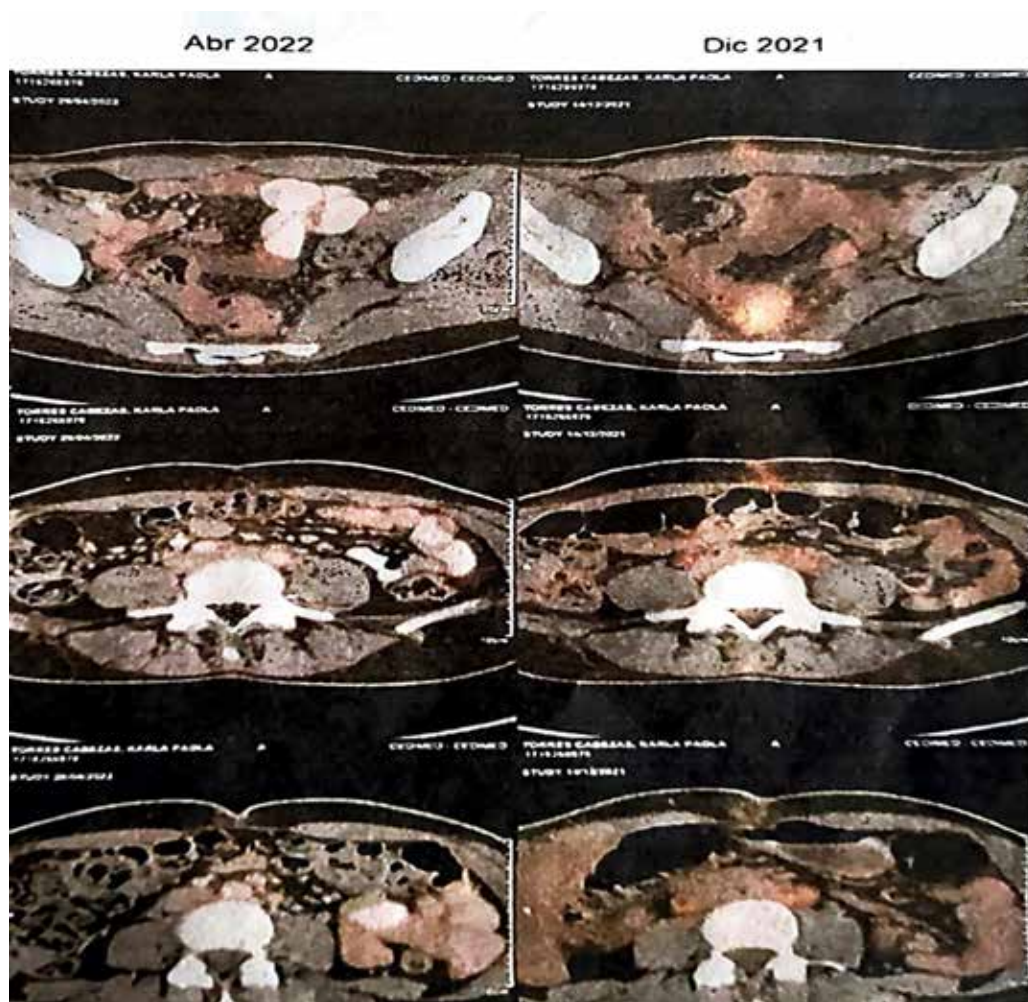
Table 4. Adverse reactions of QMT

No symptom	0	1	2	3	4	5	6	7	8	9	10	Worst symptom imaginable
Not at all exhausted												The most exhausted thing imaginable
No nausea												The worst nausea imaginable
No loss of appetite												The worst loss of appetite imaginable
No nervous hypersensitivity												Worst nervous hypersensitivity imaginable
Legend		After treatment									Before treatment	

Source: León²¹. Adaptation

3. Dependent variable 2.CEO.Tumor Pathology

Figure 1. Imaging study Dec. 2021 (before treatment) and Apr.2022 (after treatment)



Discussion

The application of O3T showed effectiveness before the culmination of the treatment, demonstrating functional capacities to carry out her routine daily activities by herself without the help of other people, increasing progressively from the first cycle her capacity to 90%; in the fifth cycle and one month after the culmination of O3T she reached 100% functioning.

The symptoms presented in the patient due to the effects of QMT presented a modal behavior of 10 on the SAS scale; however, before 28% of the application of O3T decreased favorably to a mode of 0 on the SAS scale. The disappearance of the initial symptomatology was achieved in 100%, before the completion of the O3T treatment, improving the patient's quality of health.

Tumor pathology before O3T mostro on Pet-Scan Dec. 2021:

- a) signs of tumor pathology of high metabolic grade in: solid peritoneal implant adhered to the sigmoid colon,
- b) adenopathy versus peritoneal implants in the sigmoid mesocolon;
- c) adenopathy of the left common iliac chain;
- d) left retroperitoneal para-aortic retroperitoneal adenopathy; and
- e) subsolid pulmonary nodule in the lateral segment of the right lower lobe.

After applying the O3T, in Apr. 2022 in Pet-Scan it was evidenced that:

- a) absence of tumor pathology of moderate/high metabolic grade;
- b) disappearance of pulmonary nodule of the right lower lobe; and
- c) complete response of pelvic adenopathies and pelvic peritoneal implants to QMT

Conclusions

This study demonstrated that the application of O3T in patient with CEO, increases the effectiveness of QMT and reduces its adverse effects in patient with CEO, proving a favorable correspondence between O3T and the quality of health of patient with CEO..

Conflicts of interest: None.

Financing: None

Electronic correspondence: gregorinagonzalez2020@gmail.com

References

4. Saez-Carriera R, Moreira-Romero JM, Espinoza-Ortiz EM y Ubilla-Mazzini W. (2023) Incidencia del Cáncer Oral en SOLCA-Guayaquil: Estudio retrospectivo. Rev. Cient. Esp. Odontológicas Universidad de Guayaquil. Vol.6, n°1(2023). DOI: <https://doi.org/10.53591/eoug.v6i1.1291>
5. Sociedad de Lucha contra el cáncer SOLCA. Núcleo Quito (2021). Boletín Epidemiológico. Vol.1.Año 1. Mar-abr. 2021.Ecuador. <https://www.solca.med.ec/>
6. Damián-Aucancela MC, Cubillo-Chungata KE, Basantes-Fuenmayor PD y Ruiz-Ruiz MG. (2022). Principales avances en la investigación clínica del cáncer de ovario: una revisión actualizada. Ed. 66. Vol 7, n° 1 (2022) <https://polodelconocimiento.com/ojs/index.php/es/article/view/3514>
7. Mendieta-Díaz MR, Giler-Sarmiento AD, Malla-Valdiviezo LA y Solórzano-Rosado JB. (2020). Marcadores tumorales en el diagnóstico de cáncer epitelial de ovario: caso de estudio. Rev. Cient. Dom. de las Cs. Vol. 6, n° 3, Especial sept. 2020, pp. 313-330. DOI: <http://dx.doi.org/10.23857/dc.v6i3.1400>
8. Arvelo F, Sojo F. (2023) Transición epitelio - mesenquima y cáncer. Invest. Clín. Vol.64, n°3 Maracaibo set. 2023 Epub 01-Oct-2023. <https://doi.org/10.54817/ic.v64n3a10>
9. American Cancer Society (2022). Tratamiento del Cáncer de Ovario. Ene. 5, 2022.Cancer.org/1800.227.2345

10. Reyes-Reyes E, Cuétara-Lugo EB y Alonso-Díaz T. (2023). Ozonoterapia y cáncer: mito o realidad. *Rev. Cubana de Med.*, Vol. 62, nº 1. (2023). <https://revmedicina.sld.cu/index.php/med/article/view/2962/2401>
11. Fernández-Cuadros ME, Pérez-Moro O, Albaladejo-Florín MJ y Alava-Rabasa S. (2020). El ozono intraarticular modula la inflamación, mejora el dolor, la rigidez, la función y tiene un efecto anabólico sobre la artrosis de rodilla. *Rev. Soc. Esp. Dolor* [online]. 2020, vol.27, nº2, pp.78-88. Epub 25-May-2020. ISSN 1134-8046. <https://dx.doi.org/10.20986/resed.2020.3775/2019Peñaranda-Serrano> I. (2019).
12. Peñaranda-Serrano I. (2019). ¿Es la ozonoterapia una terapia adyuvante eficaz en el paciente oncológico? Universitat de les Illes Balears. Tesis de grado. https://dspace.uib.es/xmlui/bitstream/handle/11201/150463/Penaranda_Serrano_Irene.pdf?sequence=1&isAllowed=y
13. Viebahn-Hänsler R y León-Fernández. (2021). *Medical ozone* Publisher. ISBN 978-3-949499-03-6, pp.180. <https://d-nb.info/1233514423/34>
14. Urgellés-Carreras S, López-Artze O, Álvarez-Fiallo M y Reyes-Guerrero E. (2021) Ozonoterapia en pacientes con dolor pélvico crónico. *Rev. Cubana de Medicina Militar*. 2021;50(3): e02101295. <http://scielo.sld.cu/pdf/mil/v50n3/1561-3046-mil-50-03-e1295.pdf>
15. Calzada-Borroto YD, Vivian Borroto-Rodríguez V, Hernández-Díaz B, Rachel Beath-Rodríguez R y Díaz-Valdés YN. (2023) Ozonoterapia en el dolor crónico osteoarticular. *Rev. Cubana de Reumatología*. 2023;25(1): e349. file:///C:/Users/usuar/Downloads/Dialnet
16. Fergusson J. (2023). Un estudio de caso neozelandés: el uso de la ozonoterapia como tratamiento complementario de apoyo a la radioterapia en el cáncer de próstata. Informe de un caso. *AEPRIMO*. 2 jul, 2023. Vol. 13 (2023). <https://ozonotherapyglobaljournal.es/un-estudio-de-caso-neozelandes-el-uso-de-la-ozonoterapia-como-tratamiento-complementario-de-apoyo-a-la-radioterapia-en-el-cancer-de-prostata-informe-de-un-caso/>
17. Alonso DT, Reyes RE y Cuétara LE. (2023). Ozonoterapia y cáncer: mito o realidad. *Rev. Cubana de Med.* vol.62, nº1. Ciudad de la Habana ene.-mar. 2023. <https://revmedicina.sld.cu/index.php/med/article/view/2962>
18. Clavo RN, Gutiérrez D, Gerardo S, López L, Rovira G, Martínez SG, González E, Ignacio J, Perera C, Blanco J y Rodríguez EF. (2021). La ozonoterapia como adyuvante para el tratamiento del cáncer: ¿se justifica más investigación? *Rev. CINALGIA*. 26-ene-2021.<https://clinalgia.com/la-ozonoterapia-como-adyuvante-para-el-tratamiento-del-cancer/>
19. Jaramillo PF, Morales DA y González G del C. (2024). Efectos de la Ozonoterapia Intraperitoneal en Cervicitis asociada al Virus del Papiloma Humano. *Revista Universidad de Guayaquil*. vol. 138, nº 1 - 2024 (ene-jun). <https://revistas.ug.edu.ec/index.php/rug/article/view/2353/3493>
20. Bañuelos-Ramírez AK. (2023) Cáncer y Ozono. *Revision bibliografica. Ozone Therapy Global Journal*. Vol. 13, nº 1. pp. 153-173, 2023. Official Journal of AEPRIMO (Spanish Association of Medical Professionals in Ozone Therapy). Madrid, Spain. Publicación Oficial de AEPRIMO (Asociación Española de Profesionales Médicos en Ozonoterapia). Madrid, España. file:///C:/Users/usuar/Downloads/Dialnet-CancerYOzono-9051453%20(3).pdf
21. Gavilán-Hernández TC. (2022). Potencialidades terapéuticas de la ozonoterapia en el Instituto de Hematología e Inmunología. Vol. 38, nº1 (2022). <https://revhematologia.sld.cu/index.php/hih/article/view/1435/1323>
22. Arvelo F, Sojo F. (2023) Transición epitelio - mesenquima y cáncer. *Invest. Clín.* Vol.64, nº3 Maracaibo set. 2023 Epub 01-Oct-2023. <https://doi.org/10.54817/ic.v64n3a10>
23. Del Campo JM. (2022). Cáncer de Ovario. *Sociedad Española de Oncología Médica [SEOM]*. 19 dic. -2022. <https://seom.org/info-sobre-el-cancer/ovario?showall=1&showall=1>

24. León-Clerque EM. (2021). Relación entre la capacidad funcional del paciente con cáncer y la calidad de vida del cuidador primario informal. <https://repositorio.utn.edu.ec/bitstream/123456789/11496/2/06%20TEF%20386%20TRABAJO%20DE%20GRADO.pdf>
25. Carvajal, A., Martínez, M., Centeno, C. (2023) Versión española del Edmonton Symptom Assessment Sytem (ESAS): un instrumento de referencia para la valoración sintomática del paciente con cáncer avanzado. *Rev. Med Paliat.* 2023. Vol. 20. Número 4. España